

Oxygen-Ozone Treatment of the Knee, Shoulder and Hip

A Personal Experience

P. BENVENUTI

Orthopaedic and Neurological Recovery and Rehabilitation Unit, S. Anna Hospital; Brescia

Key words: oxygen-ozone therapy, medical ozone, hip, knee, shoulder

SUMMARY - This paper describes the author's experience of treating acute and chronic disease of the large joints (knee, shoulder, hip) by intra and peri-articular injections of microdoses of an oxygen-ozone gas mixture. Three illustrative case reports are given. The patients were assessed before and after treatment. In addition to a resolution of joint pain, patients had a good functional recovery of their daily activities and the treatment was well-tolerated

Introduction

Ozone is a highly soluble gas with great oxidizing activity. In contact with biological fluids ozone forms lipid oxidation products and reactive oxygen species^{1,3,4}. These substances react with white blood cells triggering the production of cytokines, proteins strongly conditioning inflammatory reactions, and red blood cells enhancing the oxygen supply to tissues².

Ozone is used to treat many painful syndromes affecting the joints, muscles and tendons even when peripheral neurological impairment is present⁶. Its painkilling mechanism is thought to be based on stimulation of the antinociceptive apparatus mediated by endogenous opioids and serotonin thereby raising the pain threshold. In addition, the marked anti-inflammatory properties of ozone reduce oedema, joint swelling and compression on nerve root structures⁷. Ozone favours tissue hyperoxygenation following increased vascularization due to neoangiogenesis³ improving local tissue trophism and the inhibitory capacity of inflammatory metabolites.

There is a consensus in literature reports that the sum of the beneficial effects of ozone reduces local pain favouring the recovery of joint function and motion lost during the painful phase (walking, going up and down stairs, washing, dressing and feeding). Ozone injections (intra-articular, peri-articular or percutaneous) are considered a

good treatment with a high success rate, little risk of complications, easy execution, repeatability and stable outcome⁴.

Administration and Dose

After thorough examination of the patient and obtaining signed informed consent to oxygen-ozone injection, the gas mixture is administered. Ordinary sterile conditions are maintained for disinfection of the patient's skin as well as the syringe, needles and hands. The increasing use of oxygen-ozone injections to treat inflammatory-degenerative diseases of the joints has led to a specific treatment protocol defining the gas concentrations, doses and infiltration techniques to follow. Some authors favour a single intra-articular injection with or without instrumental guidance. Others prefer the peri-articular approach with injection into certain standardized painful points for each district^{4,5,8}. Experience has shown that there is no single effective dose for all patients: the ozone probably needs to reach an activation threshold to exert its potent pharmacological effects. The latest indications of the Italian Federation of Oxygen-Ozone Therapy clearly recommend smaller amounts of gas⁴ than in the past with slightly higher concentrations of ozone. The gas mixture should be injected slowly, always after aspiration. The protocol includes an initial cycle of at least five injections

at weekly intervals. The infiltration is usually painless. The route of administration and ozone dose are reported in clinical cases for each of the main joints treated^{5,8}.

Knee

The knee is the intermediate joint of the lower limb. It is mainly a joint with only one degree of freedom – flexion-extension – even though it also has a second accessory degree of freedom: rotation around the longitudinal axis of the leg which occurs only when the knee is flexed. The knee essentially works in compression, under the effect of gravity. Even though the knee joint has a good mobility under the considerable body load it must sustain, it is composed of two refined joints (one could say three). The first is the inferior distal face of the femur with two distinct joint regions and articular parts and the superior proximal face of the tibia which meets the femur with two articular parts. This anatomical arrangement suggests two separate joints each working independently and placed parallel to one another. The second joint composing the knee is the femoral-rotular (or patellar)¹⁰. During flexion, an unstable position, the knee is particularly exposed to injury to the ligaments and meniscus. In extension, when the knee is in a highly stable joint position, joint fractures or ligament rupture are more common⁹. Knee pain is the main symptom leading patients to consult a specialist. Pain may be invalidating and progressive, exacerbated by movement (while walking or going up and down stairs). Swollen knee is the second symptom: it reflects the synovial membrane reacting to joint inflammation (caused by cartilage degeneration, trauma, overloading joint structures) producing synovial fluid to better lubricate the joint.

Oxygen-ozone therapy is used to treat patients with gonarthrosis (initial and late), inflammatory disease due to overloading, patellar tendinitis, goosefoot bursitis of the knee, synovitis during inflammatory arthritis, bursitis, knee pain caused by joint cartilage degeneration due to femoral-rotular chondropathy, knee pain following surgery.

The patient is placed in a supine position with the knee in extension. After having located the patella its medial margin is pressed to sublaxation in the lateral margin to increase the articular rim as much as possible. A 21G needle is inserted along the superolateral margin of the patella (to the superior third). After thorough sepsis and aspiration, 10-15 cc of the gas mixture is injected slowly at variable concentrations depending on the disease and in any case not more than 25 µg/ml. The patient is

invited to perform some flexion-extension movements of the knee to better distribute the drug throughout the joint including the recesses.

Case Report

A 62-year-old businessman with bilateral knee pain (measured as VAS 8) prevalent on the left and with swelling of both knees (extensive on the left) with increased tactile knee temperature and no skin reddening. Physical examination disclosed painful knee joint movements throughout the range of movements with flexion possible up to 90° on the left and 110° on the right, and complete extension. Painful swelling with increased temperature and skin rubor was evident in the right metatarsal phalange probably due to gout arthritis (the patient was receiving allopurinol treatment). The patient was limited in climbing stairs (up and down) and required a support, in dressing (putting on his socks) and in walking which he managed successfully for 200-300 metres. In addition he complained of pain at night resulting in insomnia not controlled by current anti-inflammatory treatment. On medical examination he produced a knee CT scan and orthopaedic report (predating the onset of joint swelling) noting largely normal findings (“meniscal degeneration, arthrosis of the patella”) and no indication. He underwent blood tests which disclosed acute gout (uricaemia 8.1, Pcr 7.60) with probable polyarticular involvement. He then started treatment with bilateral intra-articular oxygen-ozone injection into the knees of 10 ml gas mixture at a concentration of 20 µg/ml (a clear synovial fluid was aspirated from the joint cavity but we decided not to perform arthrocentesis and to proceed with the infiltration). One week after the first treatment session there was a rapid reduction of joint swelling and pain (VAS 5) with a recovery of bilateral joint function (flexion 120°). At the end of the five weekly injections knee swelling had subsided with almost total remission of pain (VAS 2) and a complete recovery of function (going up and down stairs, walking, putting on socks). The patient was prescribed medical management for the gout (metatarsal phalange joint) per os: a full dose of allopurinol and NSAIDs. The patient did not attend the first follow-up visit one month later and let us know he was busy in a sailing competition. At a recent visit knee joint function was normal with no swelling. The painkilling effects of the oxygen-ozone treatment have persisted a long time after suspension of NSAIDs (previously during pain), the patient readily goes up and down stairs and walks normally. Further follow-up visits have been scheduled, the first in four months’ time.

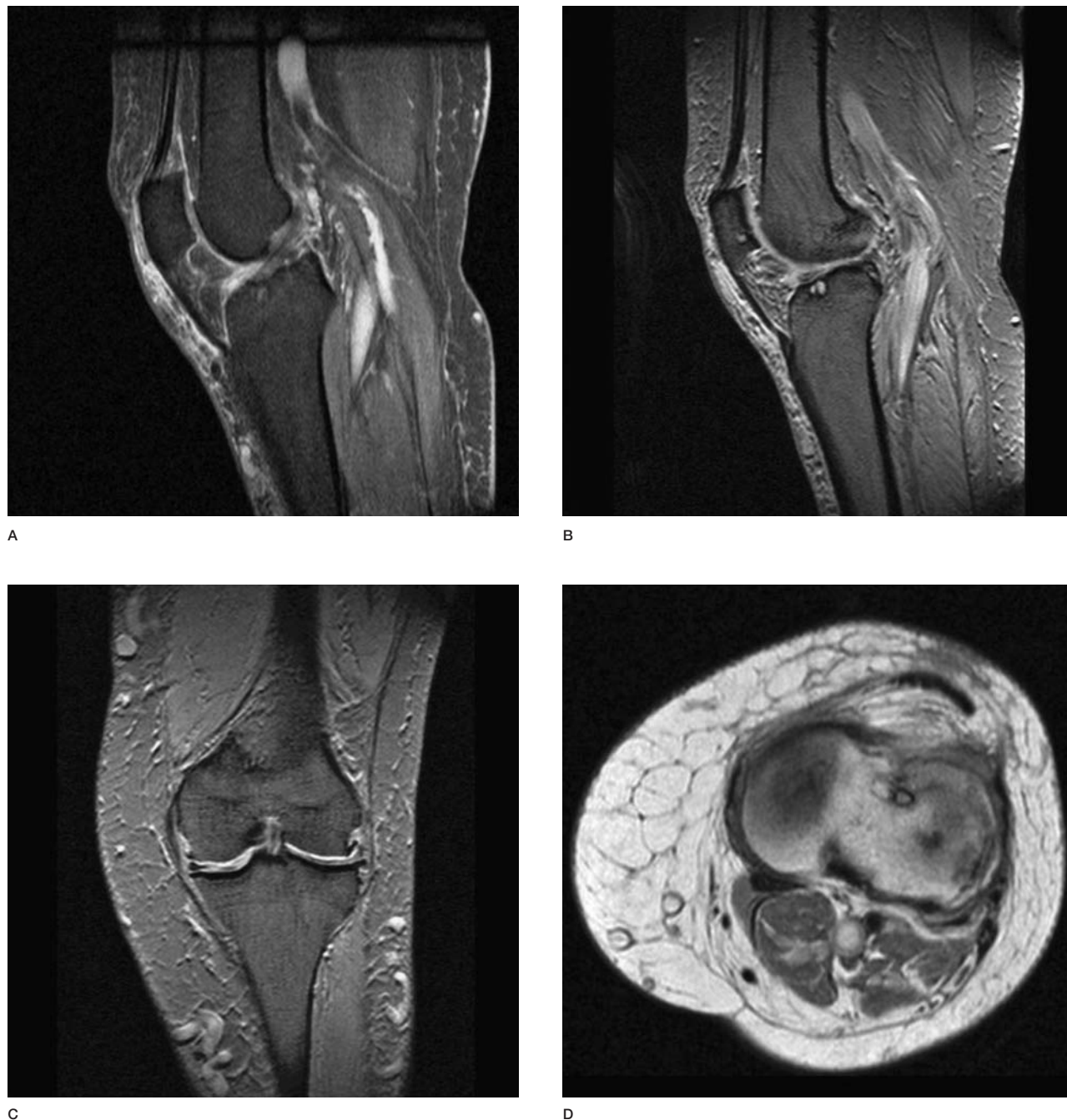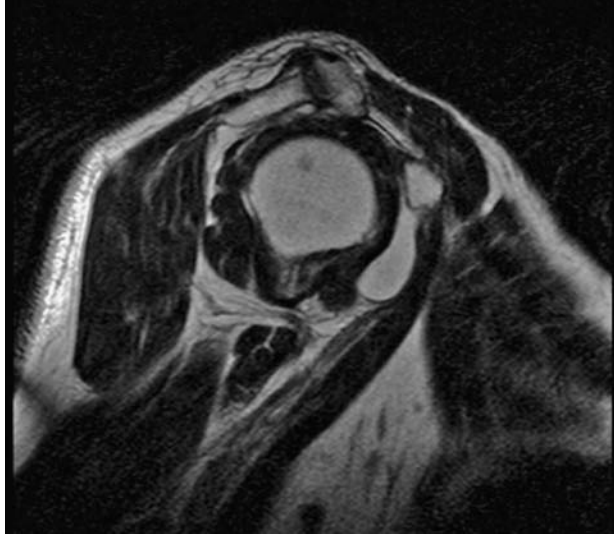


Figure 1 A-D) MR study of the knee before oxygen-ozone therapy: the scan shows femoral-rotular arthrosis with erosion of the joint cartilage pannus and marginal osteophytic appositions. Erosion of the cartilage pannus of the patella of the trochlear groove apparently without signs of subchondral injury. Continuous collateral ligaments with marked infiltrate of the lateral and medial capsulo-ligamentous compartments. Extensive bilateral degeneration of the meniscus with barely recognizable meniscal fibrocartilage and residual material extruded from the joint margin. The cartilage pannus appears thin and eroded on both condylar surfaces with signs of subchondral injury at the third middle anterior surface of the medial condyle. Fluid within the joint and infiltration of Hoffa's fat pad.

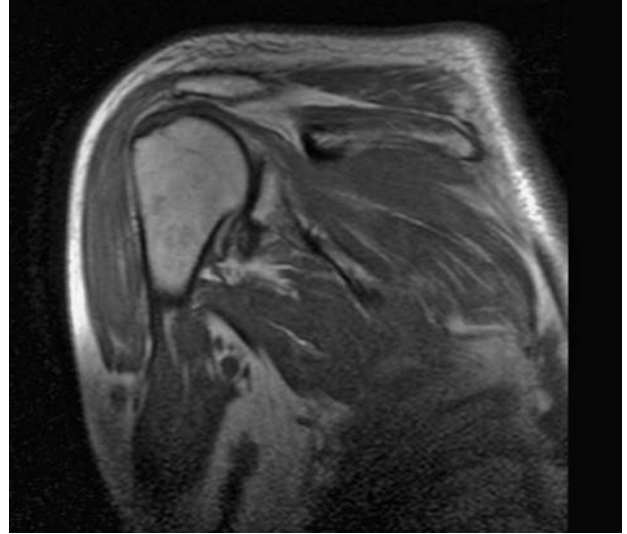
Shoulder

The shoulder has great freedom of movement and serves to orientate the hand in space and hence to perform most daily activities. The gleno-

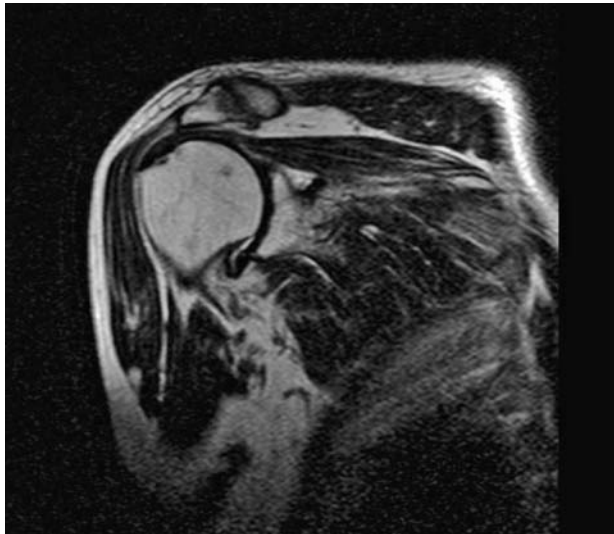humeral joint is a highly mobile but not very stable ball-and-socket joint. Its stability is ensured by the glenohumeral fibrous capsule. Joint motility depends on the rotator cuff muscles: supraspinatus, infraspinatus, teres minor and subscapularis.



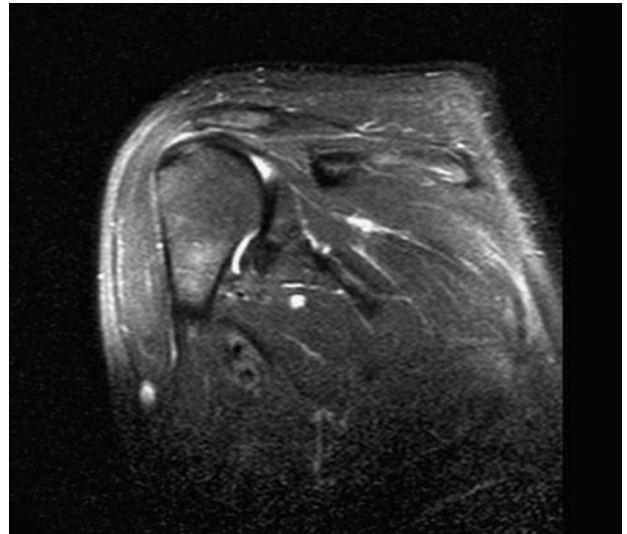
A



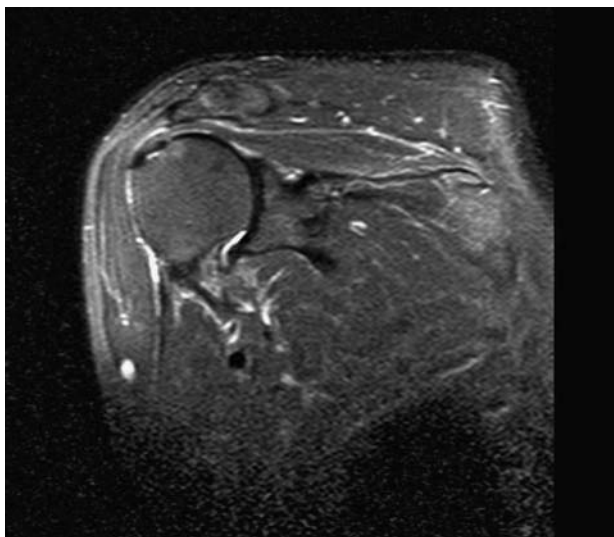
B



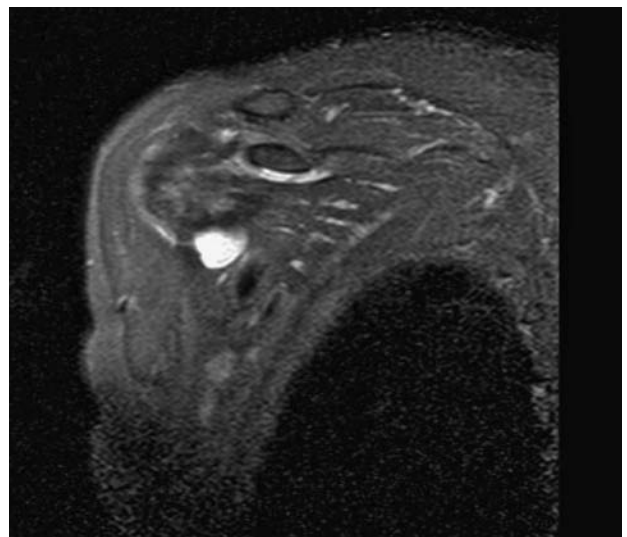
C



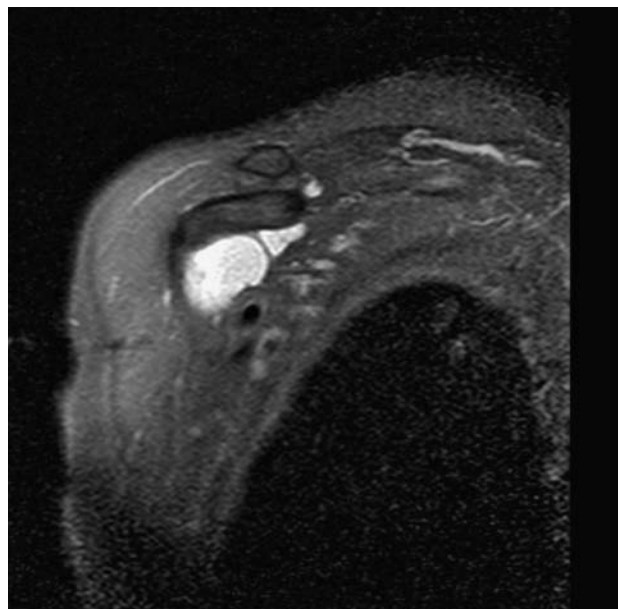
D



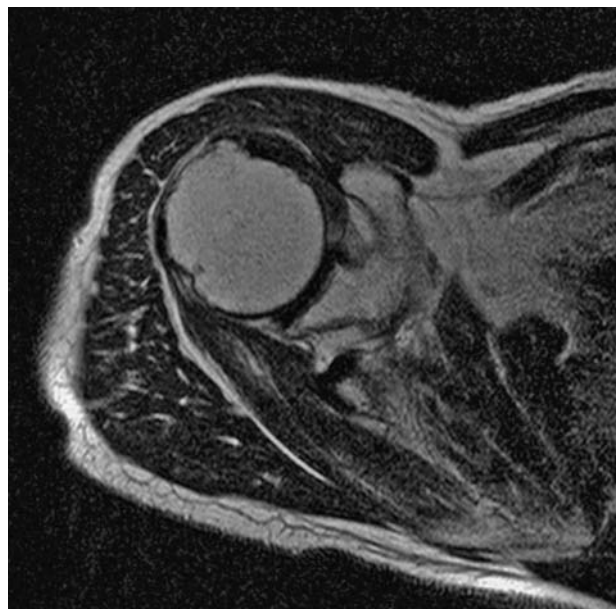
E



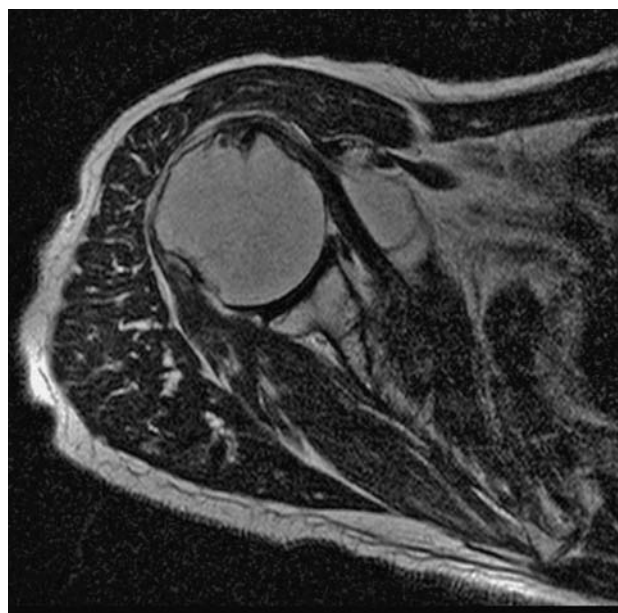
F



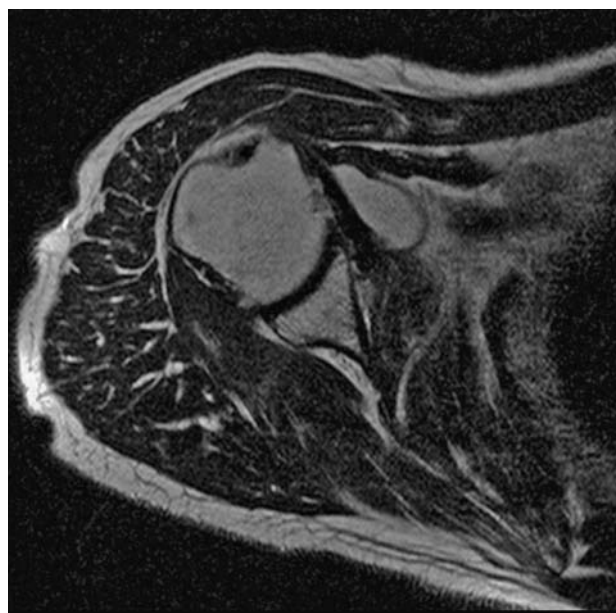
G



H



I

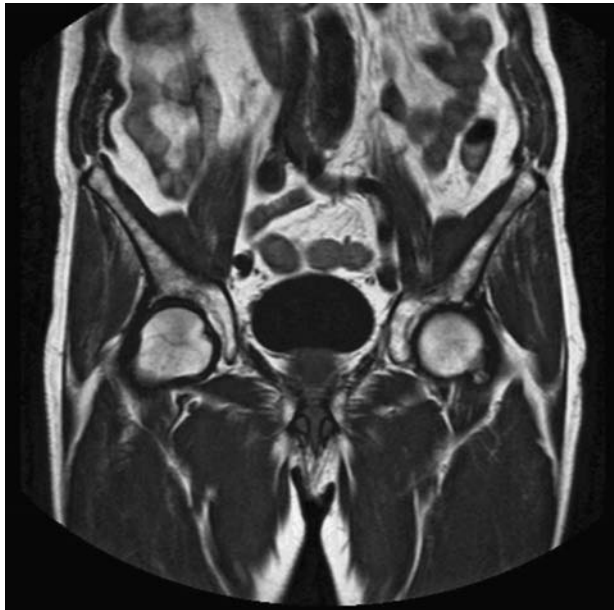


L

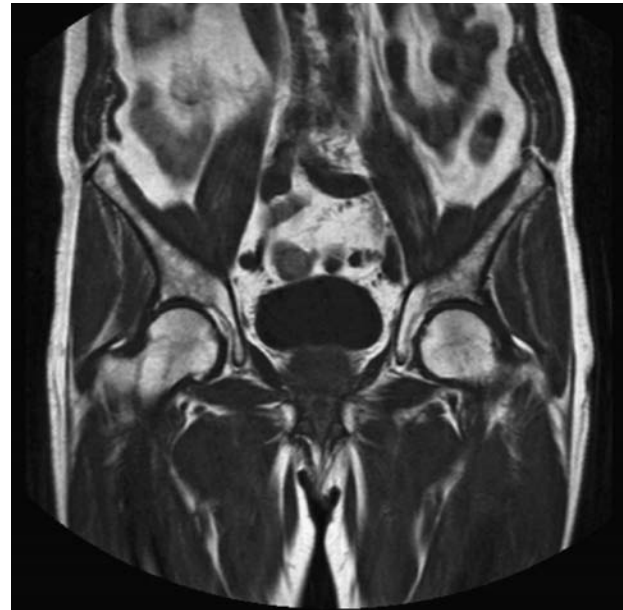
Figure 2 Shoulder MR scan after oxygen-ozone treatment. The scan shows arthrosis of the acromioclavicular joint with osteophytic appositions on the inferior joint margins impressing the supraspinatus tendon. The structure of the rotator cuff tendons is altered with degenerative changes and major impairment of the supraspinatus tendon whose anterior third is lacerated. The humeral CLB tendon is in place in the bicipital ridge. The anterior profile of the trochlea of the humerus is irregular and dystrophic. Fluid bloating of the subcoracoid bursa due to bursitis.

The suprahumeral joint is not a proper joint but plays a functional role protecting the head of the humerus. It is made up of the coracoacromial arch (coracoid process, acromion and coracoacromial ligament) and the glenoid cavity. This space

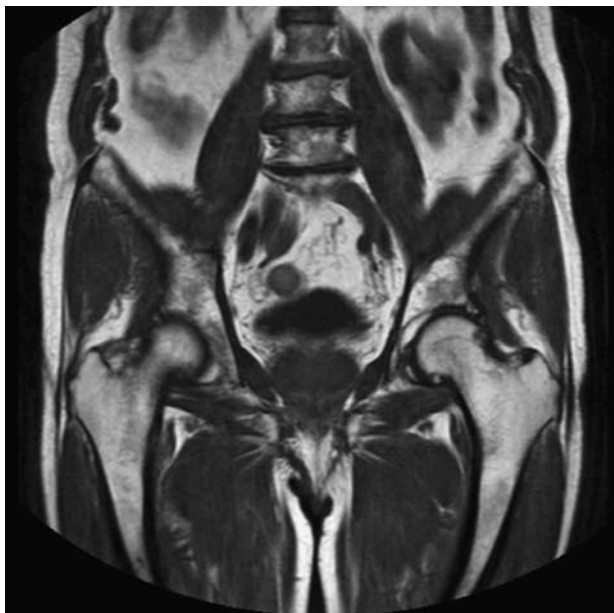
houses the subacromial and subcoracoid bursae, the supraspinatus muscle and its tendon, the glenohumeral capsule and the tendon of the long head of the biceps muscle. The acromioclavicular and scapulocostal joints regulate scapular movement



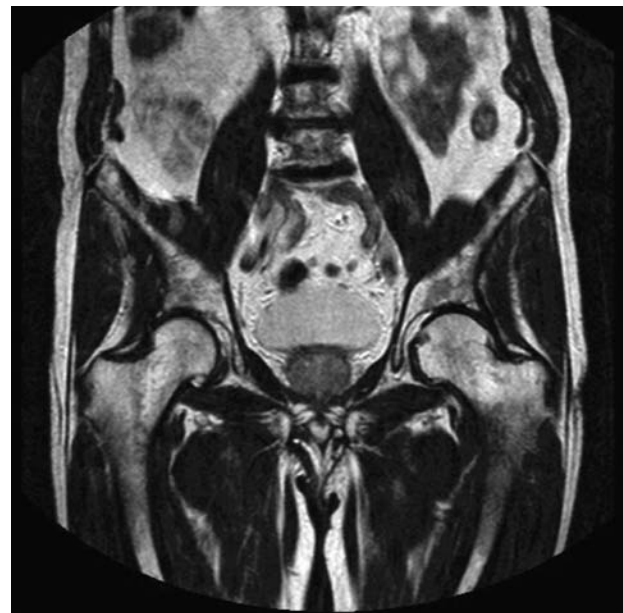
A



B



C



D

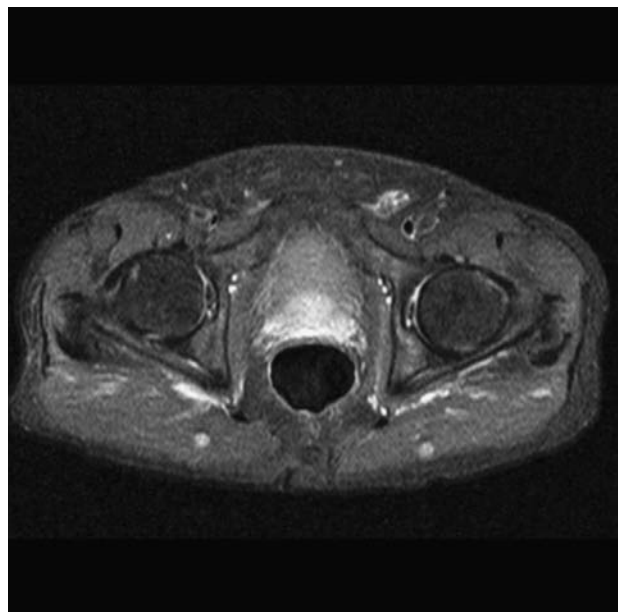
(gliding of the scapula on the rib cage) whose scapular part depends on the trapezius and dentate muscles. The synergic action of these two muscles lowers the inferior part of the scapula and rotates it externally making it rotate around the acromioclavicular joint. In turn this movement raises the glenoid cavity. All this occurs during abduction and raising of the arm.

The biceps muscle does not play an active part in glenohumeral movement and its gliding on the

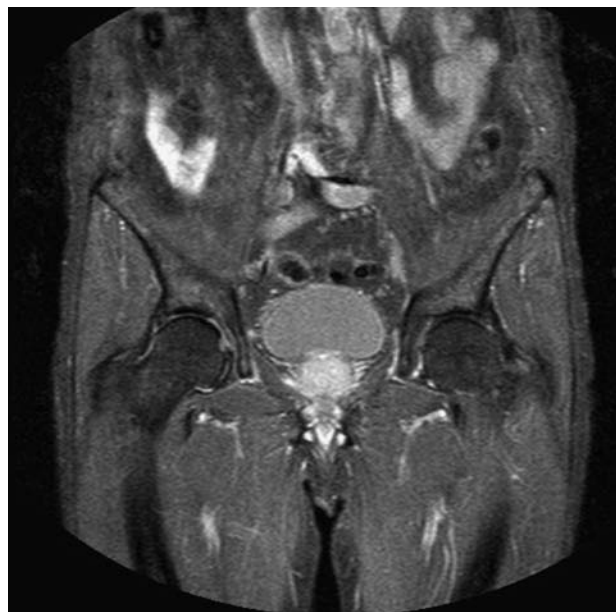
bicipital ridge during arm abduction is passive: it is the ridge that moves, whereas the muscle stays still. When this mechanism is hampered shoulder function will be impaired to some extent^{9,10}.

When a person complains of pain in the shoulder it is important to rule out an irradiated pain (e.g. from the cervical region) or a visceral pain manifesting in the shoulder (e.g. of cardiac, pulmonary, splenic or hepatic origin).

History-taking, physical examination and con-



E



F

Figure 3 A-F) MR scan showing bilateal coxarthosis mainly on the right with sclerosis of the acetabular roof and the cotyloid rim. Minimal amount of fluid within the joint. Oxygen-ozone therapy led to a complete resolution of pain with full functional recovery.

trol of active and passive movements yield useful information on the origin of pain. It is important to investigate the features of pain such as its origin and extension, bearing in mind that pain arising from the shoulder seldom extends beyond the elbow. It should also be noted how the patient presents to the doctor, the position the painful arm is kept in and how s/he undresses. This should be observed from all angles. In cases of extreme pain caused by microcrystalline bursitis, examination is

virtually impossible because of the pain (pain usually subsides after about two weeks of treatment).

The patient must be examined bare chested to search for any swelling, asymmetry and differences in level between one limb and the other and to assess muscle trophism.

Oxygen-ozone therapy is used to treat patients with inflammatory rotator cuff tendinopathy (also due to overloading), tendinitis of the supraspinatus muscle caused by impingement, tenosynovitis of

the long head of the biceps, subacromial bursitis, frozen shoulder, pain following surgery, painful shoulder in the course of inveterate rupture of the cuff.

Oxygen-ozone is injected into the shoulder via the posterior approach, laterally under the inferior margin of the acromion using a 22G needle. After aspiration and thorough asepsis up to 10cc of oxygen-ozone mixture are injected slowly at varying concentrations depending on the condition but not more than 25 µg/ml. If clinically indicated, it is also useful to puncture the subacromial bursa and the stretch of the long head of the biceps muscle with a 27G needle injecting microdoses of 0.5-1 cc.

Whenever possible oxygen-ozone therapy should be flanked by a period of rehabilitation with individually prescribed exercises.

Case Report

A 58-year-old housewife with extremely painful shoulder and severely limited joint movement presented for outpatient assessment. She had previously undergone many surgical interventions for "painful shoulder" and in April 2003 she had also undergone shoulder mobilization under narcosis in an attempt to recover even partial joint movement but without success. Before orthopaedic surgery the patient had been treated with physical therapy and steroid injections into the right shoulder without benefit. At physical examination the right shoulder showed diffuse hypertrophy of the muscles of the whole scapulo-humeral joint. Joint movement was only possible for a few degrees in abduction and flexion due to the reduction of movement caused by pain. Pain was assessed as VAS 10 and was present also at night. The patient required help getting dressed and was limited in feeding and personal hygiene movements.

She produced an MR scan report of the right shoulder (July 2004) stating the following key findings: "recurrent rupture of the shoulder rotator cuff ... extensive uncovering of the head of the humerus ... involution of the supraspinatus muscle...". Oxygen-ozone therapy was prescribed by intra-articular injection (posterior access: under the posterolateral margin of the acromion) and peri-articular infiltration (subacromial bursa + stretch of the long head of the biceps) during the same session using a total of 10 ml gas mixture at a concentration of 15 µg/ml. The patient had only a reduction of nocturnal pain one week after the first treatment session. She subsequently reported a further decrease of shoulder pain (measured as VAS 5) after another two weekly treatment sessions and an initial recovery of active shoulder motion

without pain (abduction and flexion 60°, rotations 1/3 of the movement). At the end of the treatment cycle the patient reported an almost total reduction of pain (VAS 2) and a recovery of active shoulder function: abduction and flexion more than 90°, rotation possible for more than 2/3 of the joint excursion, combined abduction and rotation movements with consequent recovery of full autonomy in her daily life. After oxygen-ozone therapy the patient started a series of exercises designed to strengthen the scapulo-humeral muscles and further regain movement in the shoulder joint.

Hip

The hip joint is a ball-and-socket joint like the shoulder. It therefore has wide possibilities of movement but whereas the arms are attached to the trunk adding weight to the body, the legs receive 80% of body weight through the femoral heads. Hip movements are achieved only through the coxofemoral joint which is highly stable and well seated. Unloading body weight onto the femoral heads is a stabilizing element facilitating the congruence of joint parts and also contributes to the ground reaction allowing maintenance of an upright posture and under dynamic conditions triggering the force required for walking and running^{9,10}. This explains how the particular function and structure of the hip expose it to ongoing mechanical stress which may be the first cause on disease onset. Patients are often not aware of a hip inflammation because they complain of pain in the anterior thigh and knee rather than the hip where the pathological process is underway. This is known as referred pain called FABER (Flexion, ABduction, External Rotation). The Faber test is simpler to perform than to describe. The patient lies down placing the heel of one leg on the knee of the other. In this position it should be possible to lower the knee to the same level of the other leg so that both knees touch the bed. If there is inflammation the Faber manoeuvre will be painful and in case of consolidated coxarthrosis then the manoeuvre cannot be performed or is only partial due to restriction of movement¹¹. When the hip starts to be limited in movements the remote symptoms are manifested not only in the thigh and knee but also in the pelvis and back. When a patient has backache or pains in the side of the pelvis the origin may lie in hip malfunction. Unable to perform certain hip movements, the patient overloads the pelvic joints and/ those of the lumbar spine.

Oxygen-ozone therapy is used to treat hip pain due to functional overload, pain caused by coxarthrosis (initial and late), trochanteric bursitis,

hip tendonitis and pain following hip surgery. Whenever possible oxygen-ozone therapy should be flanked by a period of rehabilitation with individually prescribed exercises.

The lateral approach is indicated in oxygen-ozone therapy of the hip. After having located the cranial margin of the greater trochanter and after sterilizing the area a 25G needle is inserted in a direction perpendicular to the greater trochanter and after aspiration slowly injecting 5 cc of an oxygen-ozone mixture at a concentration of 25 µg/ml.

Case Report

This method of hip infiltration is called peritrochanteric (lateral approach, perpendicular needle, single injection of 5 cc gas mixture at a concentration of 25 µg/ml) and has been successfully used to treat many patients with hip pain of different origin (coxarthrosis, muscle and tendon disease of the hip, trochanteric bursitis). In particular, we treated a 54-year-old sportsman whose hobby was running. He had already received medical management of hip pain and physical therapies (ultrasound, laser) and functional rehabilitation cycles consisting of masotherapy and joint mobilizations without benefit.

Muscle and tendon ultrasound scan at the start of the patient's diagnostic work-up showed "right trochanteric bursitis". Initial physical examination disclosed swelling in the right greater trochanter with increased tactile temperature. Right hip flexion reached 90° with painful arrest, rotations were painful (> intrarotation already at the first degrees of movement), hip pain was present on applying pressure to the greater trochanter and on con-

trasted abduction of the hip. In addition the patient referred nocturnal hip pain, difficulty putting on his socks and limp on walking with deambulation for about 50 metres. Initial pain assessment was estimated as VAS 9. The patient was treated by a cycle of five ozone therapy sessions (5 cc oxygen-ozone at a concentration of 25 µg/ml) at weekly intervals.

After the first treatment session joint pain subsided with a marked improvement in trochanteric swelling. However, the patient's hip pain had a fluctuating course during the five treatment sessions with phases of complete remission and episodic reactivation. At the end of the treatment cycle nocturnal and daytime pain assessed on the VAS score had disappeared. MR scan of the right hip at the subsequent follow-up visit five weeks after treatment ruled out the previous bursitis, thereby confirming the clinical finding. This outcome was confirmed at the MR follow-up scan four months later. The patient has had a complete recovery of hip joint movement and resumed walking without limping and going up and down stairs without difficulty. He had also resumed the sports activities he had previously abandoned. He currently attends the ozone therapy outpatients' clinic for follow-up visits and any injections to consolidate the results obtained. Our experiences are in line with current literature on the topic and demonstrate the efficacy and versatility of ozone as an agent counteracting joint pain, inflammation and swelling^{1,2,3,4,6,7} also when administered in small amounts at weekly intervals. Ozone also proved able to spread through tissues even after percutaneous periarticular administration^{4,8} with no adverse reactions whatsoever.

References

- 1 Bocci V: Biological and Clinical Effects of Ozone. Has Ozonotherapy a Future of Medicine? *Br J Biomed Sci* 56: 270-270, 1999.
- 2 Bocci V et Al: Ozonoterapia. Comprensione dei meccanismi di azione e possibilità terapeutiche. I ed Milano: Casa Editrice Ambrosiana 2000: 730.
- 3 Cardoso CC, Carvalho JCT, Ovando EC et Al: Action of Ozonized Water in Pre-clinical Inflammatory Models. *Pharmacological Research* 42: 51-54, 2000.
- 4 Fabris G, DeLuca G, Puppis M: Sicurezza ed efficacia con Ossigeno-Ozono terapia. Microdosi miscela gassosa riducono drasticamente gli effetti collaterali con aumentata compliance e migliore efficacia terapeutica. *Rivista Italiana di Ossigeno-Ozonoterapia* 4: 127-125, 2005.
- 5 Genovese E, Bonetti M, Fontana A et Al: Tecnica della infiltrazione guidata di ossigeno-ozono nelle principali articolazioni. *Rivista Italiana di Ossigeno-Ozonoterapia* 3: 121-130, 2004.
- 6 Iliakis E: Utilizzo dell'ossigeno-ozonoterapia nella pratica ortopedica. *Acta Toxicol. Ther* vol. XVII, n° 2-3: 249-253, 1996.
- 7 Bianco G, Minonzio L: Ossigeno-ozonoterapia nel trattamento della lombalgia conseguente a ernia discale: studio prospettico su 23 pazienti. *Rivista Italiana di Ossigeno-ozonoterapia* 4: 127-135, 2005.
- 8 Ikonomidis ST, Iliakis E et Al: Non Operative Treatment of Shoulder Impingement Syndrome with Topical Injections of Medical Oxygen-Ozone Mixture. A Double Blind Clinical Trial. *Rivista Italiana di Ossigeno-Ozonoterapia* 1: 37-40, 2002.
- 9 Kapandji IA: Fisiologia articolare. 1°, 2° volume. Maloine Monduzzi editore: 74, 12.
- 10 Pirola V: Cinesiologia, il movimento umano. Ed. Ermes: 194-200, 311.
- 11 Basaglia N: Trattato di Medicina Riabilitativa. Idelson Editore.

Dr P. Benvenuti
Orthopaedic and Neurological Recovery and
Rehabilitation Unit
Sant'Anna Hospital
Via del Franzone 31
25100 Brescia
E-mail: dott.benvenuti@libero.it