

The effect of rectal ozone on the portal vein oxygenation and pharmacokinetics of propranolol in liver cirrhosis (a preliminary human study)

Saad Zaky,¹ Ehab Ahmad Fouad^{2,3} & Hassan Ibrahim Mohamad Kotb⁴

¹Department of Tropical Medicine and Gastroenterology, Faculty of Medicine, Assiut University, Egypt,

²Department of Pharmaceutics, College of Pharmacy, King Saud University, P.O. Box 2460, Riyadh 11451, Saudi Arabia, ³Department of Pharmaceutics, Faculty of Pharmacy, Assiut University and

⁴Department of Anaesthesia, Faculty of Medicine, Assiut University, Assiut, Egypt

WHAT IS ALREADY KNOWN ABOUT THIS SUBJECT

• Experimental work has shown that ozone protected both the liver and kidney from reperfusion injury through release of mediators of nitric oxide. Rectal ozone increased oxygenation in the intestinal wall (250%), portal vein (134%) and liver parenchyma (127%) in experimental animals. The kinetics of propranolol and other oxidation-dependent drugs have been reported to be affected due to liver cirrhosis. Several experimental studies have reported improved propranolol clearance through increased hepatic blood flow.

WHAT THIS STUDY ADDS

• This current study looked for evidence in man of improved hepato-splanchnic oxygenation after rectal ozone. Changes in metabolic pathway via measurement of portal vein oxygenation and the kinetic profile changes of propranolol as an index drug for metabolic oxidation in the liver were measured.

• This small preliminary clinical study showed that improved propranolol clearance was obtained by rectal ozone in humans for the first time. In addition there was also evidence of improved portal vein oxygen tension and saturation after rectal ozone. This study has a potential clinical significance.

Correspondence

Dr Saad Zaky, Department of Tropical Medicine and Gastroenterology, Faculty of Medicine, Assiut University, Egypt.

Tel.: +20 08 8230 1484

Fax: +20 08 8233 3327

E-mail: saadzky@yahoo.com

Keywords

liver cirrhosis, ozone, pharmacokinetics, portal vein oxygenation, propranolol

Received

22 May 2010

Accepted

23 October 2010

AIM

The aim of this study was to investigate the effect of rectal ozone on portal vein oxygenation and the pharmacokinetic changes of propranolol in patients with liver cirrhosis.

METHODS

Fifteen patients with liver cirrhosis were included. They were given a fixed oral dose of propranolol 80 mg on the morning of day 1 after overnight fasting. Blood samples were collected at fixed time intervals for 24 h. Patients were given 12 sessions of rectal ozone of 300 ml of 40% ozone/oxygen mixture. On day 14 another oral dose of 80 mg propranolol was given and blood samples were collected as on day 1. Plasma concentrations of propranolol were measured by HPLC. Portal vein oxygen tension and saturation were measured before and after rectal ozone.

RESULTS

Plasma concentrations of propranolol were reduced after ozone therapy with pronounced decreases in the maximum plasma concentration and the area under the plasma concentration-time curve. The changes were consistent with a decrease in propranolol bioavailability. There was a decrease in the elimination half-life and mean residence time. Portal vein oxygenation significantly increased after rectal ozone.

CONCLUSIONS

The changes in the pharmacokinetics of propranolol probably reflect an increase in the rate and extent of its metabolism resulting from improved portal vein oxygenation attributable to the ozone therapy. The present work highlights that ozone can be an alternative medical measure to improve portal vein oxygenation in liver cirrhosis.

Introduction

The oxygen limitation theory envisages that sinusoidal capillarization results in a significant limitation of access of free oxygen supply to hepatocytes. This theory is supported by the observations of a relative lack of drug metabolism by conjugation compared with oxidative drug metabolism when there is reduced oxygenation in healthy liver tissue *in vitro* (the relative sparing of drug conjugation in cirrhosis and biochemical evidence of hepatic intracellular hypoxia in cirrhosis [1]).

Hichley *et al.* reported that, in isolated perfused cirrhotic rat liver, propranolol clearance was much more sensitive to reduction in oxygen delivery than in the healthy liver [2]. Le Couteur *et al.* reported an improved propranolol clearance via increased hepatic arterial flow in perfused cirrhotic liver. The increased sensitivity of oxidative metabolism to reduced oxygen delivery observed in these studies and the improved metabolism of propranolol through increasing O₂ delivery led to the prediction that strategies to increase oxygen delivery to the liver would improve liver function [3].

Ozone therapy has been shown to increase muscle and tumour oxygenation by direct measurement using polarographic electrodes [4, 5]. Beside its well known upregulating effect as an antioxidant, ozone has been actively investigated as a protective against free radical damage associated with liver disorders via nitric oxide generation and cellular redox balance, which suggest an important clinical implication particularly in the view of increasing liver transplantation programmes [6]. In addition ozone protected against hepatic ischaemia reperfusion injury in several studies [7]. Knoch & Klug reported enhanced oxygenation of the intestinal wall (250%), portal vein (134%) and liver parenchyma (127%) after rectal insufflation of an ozone-oxygen mixture in animal experiments [8]. Propranolol is a marker of phase I metabolism because more than 90% of propranolol is metabolized by oxidation and is well characterized in normal and cirrhotic liver.

Although studies have shown effects of ozone on physiological processes, it is not generally accepted as a valuable or proven therapy.

This current study is looking for evidence in man of improved hepato-splanchnic oxygenation after rectal ozone using changes in the metabolic pathway via measurement of portal vein oxygenation and the kinetic profile changes of propranolol as an index drug for metabolic oxidation in the liver.

Methods

The study protocol was reviewed and approved by the Ethics Committee of Assiut Faculty of Medicine. This study included 15 patients with liver cirrhosis selected from

among those admitted to the department of Tropical Medicine and Gastroenterology.

A written consent was taken from the patients to be included in this study after complete and clear explanation of the nature, role and safety of the ozone therapy. They were diagnosed according to the known clinical, ultrasonographic and laboratory criteria. They were subjected to the following:

- Thorough history taking to exclude those who received propranolol,
- Meticulous clinical examination,
- Abdominal ultrasonography,
- Laboratory investigations including: liver function tests (prothrombin time, total and differential bilirubin, total protein, albumin, ALT, AST and ALP) and blood picture before and after ozone rectal insufflation.

The patients were given a fixed dose of propranolol 80 mg at the morning of the first day of the study after overnight fasting. Blood samples were then collected at 0.5, 1, 1.5, 2, 2.5, 3, 4, 5, 6, 8, 10, 12 and 24 h with meticulous observation of the pulse and blood pressure.

On the second day all patients received a rectal enema and they were given 12 daily sessions of rectal ozone insufflation at a dose of 300 ml of 40% ozone/oxygen mixture slowly within 30 min. The ozone/oxygen mixture was freshly prepared from an ozone generator (of medical use) (Humazone Promedic, HUMARES, Germany), which is automated and standardized for time, volume and concentration. Plastic ozone resistant syringes and rectal tubes were used for rectal insufflation. Then, the patients were asked to lie recumbent and to avoid passing flatus for at least 30 min.

On day 14, a similar fixed dose of 80 mg propranolol was given to all patients after overnight fasting, as and blood samples were collected at the same time intervals as for day 1 before ozone treatment with close observation of the pulse and blood pressure.

All blood samples were collected in heparinized tubes and immediately centrifuged. The plasma was separated and stored refrigerated at -20°C until analysis.

Plasma concentrations of propranolol were measured by high-pressure liquid chromatography (HPLC). Plasma (0.2 ml) was deproteinized with acetonitrile (0.2 ml), and then a portion (100 µl) of the supernatant was analyzed on an ODS/TM (5 µm, 25 cm × 4.6 mm i.d) column using a flow rate of 1 ml min⁻¹ and fluorescence detection at excitation/emission wavelengths: 290/358 nm. The mobile phase was made up with ammonium acetate buffer (pH 4.0) : methanol (50 : 50). The propranolol concentration in the sample was determined using a calibration curve prepared by peak height. The calibration curve was linear over the range of between 8 and 200 ng ml⁻¹, with a correlation coefficient of 0.998. The last sample was injected after the addition of external 10 ng ml⁻¹ propranolol and subtract-

ing in calculation. The limit of detection was 9 ng ml⁻¹ and interassay coefficient of variation (CV) was 6.2%.

Plasma propranolol concentration vs. time data were plotted for comparison of propranolol concentrations before and after ozone treatments. The data obtained were maximum plasma concentration (C_{max}) and time to reach it (t_{max}). Noncompartmental pharmacokinetics were applied to estimate pharmacokinetic parameters [9]. The area under the curve (AUC) was calculated by the linear trapezoidal rule. The relative changes in the AUC, half-life ($t_{1/2}$), C_{max} , and mean residence time (MRT) (%) of propranolol after treatment with ozone compared with that before treatment for each patient were calculated from the change in geometric mean parameters.

The other estimated parameters included $MRT = AUMC/AUC$ and the total body clearance $CL/F = D/AUC$, where CL is total body clearance, F is the absolute bioavailability and D is the drug dose. The volume of distribution (V) was also calculated as ratio to F where $V/F = D/(AUC \times \lambda_z)$, and λ_z is the elimination rate constant calculated from the slope of the terminal elimination phase. Geometric means and 90% confidence intervals were calculated for the pharmacokinetic parameters.

The patency of the portal vein was assessed by duplex ultrasonography. Two portal blood samples (one at day 1 before the start of ozone and the other within 0.5 h after the last rectal ozone session) were taken under ultrasonographic guide using a spinal needle (22 gauge) in heparinized syringes. Portal vein oxygen tension and saturation were measured using a blood gas analyzer (IC-Synthesis, USA). Follow-up of these patients for a possibility of portal vein complications was done up to 3 weeks after portal vein sampling using duplex ultrasonography.

All results were analyzed with SPSS version 11 for Windows and are presented as mean \pm SD, Geometric means and 90% CIs were calculated for the pharmacokinetic parameters before and after treatments with ozone and Wilcoxon Signed Ranks Test was used to study differences between portal vein oxygen tension and saturation before and after ozone where the significant level is stated.

Results

All the selected patients were males and their age ranged between 42 and 60 years with a mean of 50.17 ± 5.12 years. Their mean weight was 65.2 ± 2.1 kg. They had liver cirrhosis Child A (nine patients) and Child B (six patients) according to the Child-Pugh classification.

Mean plasma concentrations of propranolol in patients with liver cirrhosis declined after ozone treatment throughout the study reaching a significant reduction at 3, 4 and 24 h ($P < 0.05$) Figure 1, with a significant decrease in C_{max} . However, there was no change in t_{max} . The area under the blood concentration-time curve (AUC) showed a decrease of 63% of its value after ozone treatment. The

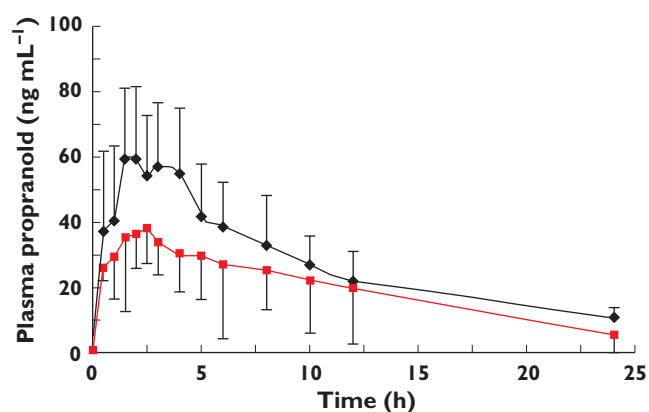


Figure 1

Mean plasma concentration profile of propranolol (\pm 1SD) in cirrhotic patients before and after treatment with ozone. Mean before ozone (\blacklozenge); Mean after ozone (\blacksquare)

Table 1

Pharmacokinetic parameters of propranolol in cirrhotic patients before and after treatment with ozone

Parameter	Mean before	Mean after	% change
$t_{1/2}$ (h)	7.889	4.811	60.99
90% CI	5.507, 12.965	3.349, 7.805	
AUC (ng ml ⁻¹ h)	822.38	304.525	37.03
90% CI	520.4, 1341.1	206.6, 464.0	
$V/F/kg$ (l kg ⁻¹)	17.037	28.06	
90% CI	10.006, 30.336	19.707, 40.456	
$CL/F/kg$ (l h ⁻¹ kg ⁻¹)	1.497	4.041	
90% CI	0.877, 2.541	2.76, 6.133	
C_{max} (ng ml)	63.214	37.745	59.71
90% CI	50.521, 81.134	28.117, 52.81	
MRT (h)	16.438	11.376	76.50
90% CI	11.635, 24.923	8.901, 15.453	
t_{max} (h)	2.335	2.121	
90% CI	1.677, 3.323	1.006, 3.994	

AUC: area under concentration-time curve, $V/F = D/(AUC \times \lambda_z)$, V : volume of distribution, F : absolute bioavailability, λ_z : the elimination rate constant, D : drug dose, CL : total body clearance $CL/F = D/AUC$, C_{max} : maximum plasma concentration, MRT: mean residence time, t_{max} : time to reach maximum plasma concentration, 90% CI: 90% confidence interval, Mean before and after are the geometric mean, % change = (geometric mean after/geometric mean before) \times 100.

pronounced decreases in C_{max} and AUC are consistent with a decrease in propranolol bioavailability.

The changes in the pharmacokinetic parameters presented in Table 1 reflect the increase in the elimination process of propranolol. As propranolol is eliminated as metabolites (the major metabolite is 4-hydroxy propranolol), this means an improvement in the process of its metabolism. Also, CL/F values were significantly increased after ozone therapy (Table 1). Consequently, most of the kinetic parameters were significantly decreased, for example, $t_{1/2}$, MRT, C_{max} and relative AUC. Portal vein oxygen tension and saturation were significantly increased after

Table 2

Portal vein oxygenation before and after rectal ozone

	Before ozone	After ozone	P value*
Portal vein oxygen tension (mmHg)			0.001
Mean ± SD	45.27 ± 5.42	61.53 ± 10.91	
Range	36.0–52.0	49.0–86.0	
Portal vein oxygen saturation (%)			0.001
Mean ± SD	82.01 ± 5.42	90.37 ± 4.20	
Range	71.0–89.4	80.0–96.2	

*Wilcoxon Signed Ranks Test.

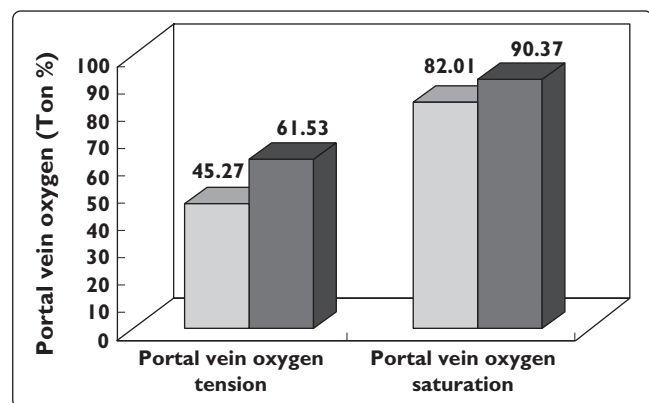


Figure 2

Portal vein oxygenation before and after rectal ozone insufflation. Before Ozone (□); After Ozone (■)

rectal ozone as shown in Table 2 and Figure 2. Follow-up of the patients for 3 weeks after portal vein sampling showed no evidence of portal vein complications using duplex ultrasonography.

Liver function tests were done before and after ozone therapy and showed a significant reduction in the prothrombin time from 17.51 ± 1.9 to 16.36 ± 1.9 s ($P = 0.015$). However no significant changes were found in other parameters. A reduction of the baseline heart rate up to 30% was observed after oral administration of propranolol from 90 to 62 beats min^{-1} and this correlated with C_{max} . After ozone therapy, a 10% reduction of the heart rate was observed. No significant changes in the blood pressure were observed.

Discussion

The pharmacokinetics of propranolol have been extensively studied in normal volunteers and in patients with various disease states. In normal volunteers, propranolol is almost completely absorbed after oral administration but its bioavailability is low (25%) because of the extensive

presystemic metabolism with an elimination half-life of 2 to 4 h [10]. In hepatic cirrhosis the systemic clearance of propranolol decreases and the systemic bioavailability of orally administered drug increases [11]. This is correlated with altered hepatic haemodynamics and functional hepatocytes as well as changes in liver enzyme activity. As propranolol is a marker of oxidation metabolism, it is largely affected by enzymes belonging to the cytochrome P (CYP) family [11].

In this trial, we have set out to assess the clearance kinetics of propranolol in patients with liver cirrhosis before and after the administration of ozone by the rectal route. Patients served as their own control. The main findings from this current study were the decreased bioavailability and improved clearance of propranolol after rectal ozone therapy in patients with liver cirrhosis. The improved clearance of propranolol, which is dependent on enzyme activity phase I metabolism, is primarily dependent on oxygenation rather than hepatic blood flow. This has been confirmed by the increased portal vein oxygenation measured in this study which reached normal oxygen saturation in the portal vein of healthy subjects (85%) [12]. The oxygen limitation theory is important because it leads to the prediction that strategies to optimize liver oxygenation will improve liver function [1]. Our strategy was based upon the premise that increased hepatosplanchnic oxygenation would improve propranolol metabolism after rectal ozone. We confirmed this by the observed increase of portal vein oxygenation after rectal ozone. This evidence was supported by the observation that rectal ozone increased portal blood oxygenation by 134% in animal experiments as reported by Knoch & Klug [8]. This study describes a new concept that the pharmacokinetics of propranolol in liver cirrhosis depend upon the portal vein oxygenation after rectal ozone. In conclusion, it seems from the above mentioned results that ozone can be an alternative medical measure to improve portal vein oxygenation in liver cirrhosis. This study has some limitations: the lack of measurement of the major metabolite of propranolol and the attribution of the change in the AUC after ozone could have been strengthened by repeating the pharmacokinetics in the same patients after a further 14 days off treatment. Lastly, the limited number of the patients may be criticized but it is an experimental concept that needs further large sample studies.

Competing interests

There are no competing interests to declare.

REFERENCES

- Morgan DJ, Mclean AJ. Therapeutic implication of impaired hepatic oxygen diffusion in chronic liver disease. *Hepatology* 1991; 14: 1280–2.

- 2** Hichely PL, Mclean AJ, Angus PW, Choo EF, Morgan DJ. Increased sensitivity of propranolol clearance to reduced oxygen delivery in the isolated perfused cirrhotic rat liver. *Gastroenterology* 1996; 111: 1039–48.
- 3** Le Couteur GD, Hickey H, Harrey PJ, Gready J, Mclean AJ. Hepatic artery flow and propranolol metabolism in perfused cirrhotic rat liver. *J Pharmacol Exp Ther* 1999; 289: 1553–8.
- 4** Clavo B, Pérez JL, López L, Suárez G, Lloret M, Rodríguez V, Macías D, Santana M, Morera J, Fiuza D, Robaina F, Günderoth M. Effect of ozone therapy on muscle oxygenation. *J Altern Complement Med* 2003; 9: 251–6.
- 5** Clavo B, Perez JL, Lopez L, Suarez G, Lloret M, Rodriguez V, Macias D, Santana M, Hernandez MA, Matin-Olive R, Robaina F. Ozone therapy for tumor oxygenation: a pilot study. *Evid Based Complement Alternat Med* 2004; 1: 93–8.
- 6** Ajamieh HH, Menendez S, Martinez-Sanchez G, Candelario Jalil E, Giuliani AL, Fernandez OSL. Effect of ozone oxidative preconditioning on nitric oxide generation and cellular redox balance in a rat model of hepatic ischemia reperfusion. *Liver Int* 2004; 24: 55–62.
- 7** Peralta C, León OS, Xaus C, Prats N, Sala Planell E, Puig-Parellada P, Gelpí E, Roselló-Catafau J. Protective effect of ozone treatment on the injury associated with hepatic ischemia reperfusion: antioxidant–pro-oxidant balance. *Free Rad Res* 1999; 31: 191–6.
- 8** Knoch HG, Klug W. Ozone-oxygen therapy in proctology. *Ter Arkh* 1990; 62: 93–8.
- 9** Shargel L, Yu ABC. *Applied Biopharmaceutics and Pharmacokinetics*, 3rd edn. New York: Prentice-Hall International Inc, 1993.
- 10** Duchateau GS, Zuidema J, Merkus FW. Bioavailability of propranolol after oral, sublingual and intranasal administration. *Pharmacokin Res* 1988; 3: 108–11.
- 11** Mclean AJ, Morgan DJ. Clinical pharmacokinetics in patients with liver cirrhosis. *Clin Pharmacokin* 1991; 1: 42–69.
- 12** Morgan GE, Mikhail MS, Murray MJ. Hepatic physiology and anesthesia. In: *Clinical Anesthesiology*, 4th edn. Section 4, Chapter 34. Morgan GE, Mikhail MS, Murray MJ, eds. New York: McGraw-Hill Companies, 2006; 708–23.